

Lateral Hardinge's versus Posterior Southern Moore's Approach in Total Hip Arthroplasty-A Prospective Cohort Study

Madhan Jeyaraman*, Ravinath TM, Ajay SS, Sabarish K and Ravi Weera AV

Department of Orthopaedics, JJM Medical College, Davangere, India

*Corresponding author: Madhan Jeyaraman, Junior Resident, Department of Orthopedics, JJM Medical College, Davangere, Karnataka, India, Tel: +91 83106 00785; E-mail: madhanjeyaraman@gmail.com

Received date: June 03, 2019; Accepted date: June 26, 2019; Published date: July 06, 2019

Copyright: © 2019 Jeyaraman M, et al. This is an open-access article distributed under the terms of the Creative Commons Attribution License, which permits unrestricted use, distribution, and reproduction in any medium, provided the original author and source are credited.

Citation: Jeyaraman M, Ravinath TM, Ajay SS, Sabarish K, Weera RAV (2019) Lateral Hardinge's versus Posterior Southern Moore's Approach in Total Hip Arthroplasty-A Prospective Cohort Study. J Clin Exp Orthop Vol.5 No.2:67.

Abstract

Introduction: Degenerative hip disorders are one of the most common and debilitating musculoskeletal disorders with increased morbidity and decreased quality of life. Total hip arthroplasty is a novel surgical procedure which has relieved millions of people from incapacitating pain arising from the hip joint. Posterior approach for total hip arthroplasty is the most commonly performed surgery with ease to operate with less tissue dissection and blood loss, whereas lateral approach is having an advantage of better exposure of acetabulum and fewer chances of dissection at the cost of extensive tissue dissection.

Objective: To study the functional outcome and the complications associated with total hip arthroplasty by Hardinge's vs Moore's approach using a modular prosthesis.

Materials and Methods: The selection of patients was randomized by selecting every alternate case of degenerative hip disease by Hardinge's (Group 'L') or Moore's (Group 'P') approach. We recruited 89 cases for this study and all cases were operated by the same surgeon. The preoperative, intraoperative parameters and postoperative events were compared with both the surgical approaches. All patients were followed up regularly according to our study protocol and were evaluated functionally with Modified Harris' Hip scores.

Results: The functional evaluation with Modified Harris hip score showed excellent results in 32 patients (68.08%), good in 13 patients (27.65%) and poor in 2 patients (4.25%) in group 'L' and excellent in 26 patients (61.90%), good in 13 patients (30.95%) and poor in 3 patients (7.14%) in Group 'P'. The complications rate was higher in group 'P' when compared to Group 'L'. With proper patient selection, adequate planning, armamentarium and meticulous surgical technique, we have achieved results comparable to other authors. Long term studies are necessary to study the late complications and to prove the efficacy of the implants and procedure. The correlation analysis with Spearman's Rank correlation coefficient showed a highly positive correlation between Hardinge's approach (Group 'L') and complications (ρ 'p' = 0.83) than the moderately positive correlation between Moore's approach (Group 'P') and complications

(ρ 'p' = 0.59). There is a significant statistical difference between surgical approach (Hardinge's and Moore's) and complications between two groups with $p < 0.05$.

Conclusion: We conclude that Hardinge's approach for total hip arthroplasty using a modular prosthesis is a rewarding procedure with excellent exposure of proximal femur and acetabulum which avoids trochanteric osteotomy and can be used for primary or revision procedures and it permits early mobilization of the patient following surgery.

Keywords: Total hip arthroplasty; Hardinge's approach; Moore's approach

Introduction

Disease/Trauma which involves the hip joint disables the individual from his day-to-day activity. Degenerative hip disorders are one of the most common and debilitating musculoskeletal disorders with increased morbidity and decreased quality of life [1]. Total hip arthroplasty with an artificial prosthesis is a reconstructive procedure that has improved the management of degenerative disorders of the hip joint that have responded poorly to conventional medical therapy and improved the functional quality of life by providing the stable, painless and mobile hip joint [2].

Total hip arthroplasty was introduced as a panacea to relieve the intractable pain of hip arthritis. The additional objectives of deformity correction and restoration of hip joint mobility and stability were achieved later with total hip arthroplasty. Total hip arthroplasty has revolutionized and provided millions of patients with an ability to lead a normal life [3]. Total Hip Arthroplasty represents the greatest single advance in modern orthopedic surgery. Arthroplasty of damaged cartilage surfaces with artificial bearing surfaces has enabled the surgeon to improve function and relieve pain in the vast majority of patients [4].

Currently, the most common methods of performing total hip arthroplasty utilize combinations of cemented or non-cemented acetabular and femoral components. A number of surgical approaches to the hip joint exist, each with unique advantages and disadvantages [1] The direct lateral (Hardinge's) approach of

hip allows the adequate access for orientation of implant, for insertion of the cement and for correction of leg length discrepancy and thus by permitting early mobilization of the patient following surgery. The posterior (Moore's) approach permits for easy access with less tissue dissection and blood loss while increasing the risk of neurovascular injury and post-operative dislocation of the prosthesis [5-7].

Objective

To study the functional outcome and the complications associated with total hip arthroplasty using modular prosthesis by Hardinge's vs Moore's approach.

Materials and Methods

Patient's recruitment

With level IV evidence, a prospective cohort study was performed from September 2016 to August 2018 in the Department of Orthopaedics, JJM Medical College, Davangere, Karnataka, India. The patients for this study were recruited by convenient sampling technique. All 89 patients were clinically and radiologically confirmed for the need of total hip arthroplasty. 89 patients were divided into two groups namely group 'L' (n=47) received total hip arthroplasty by lateral Hardinge's approach and group 'P' (n=42) received total hip arthroplasty by posterior Moore's approach. The follow up were done at the end of 1st, 3rd and 6th month and every 1 year thereafter with modified Harris Hip score.

The patients above the age of 18 years, patients with definite indications for total hip arthroplasty (AVN hip, osteoarthritis hip, malunited acetabular fracture, the non-union neck of femur fracture), patients with normal septic profile and patients who are willing to undergo total hip arthroplasty according to our protocol were included in the study. The patients aged less than 18 years, patients with positive septic screen and patients who are not willing and unfit for surgical management according to our protocol were excluded from the study.

Preoperative assessment

After getting informed and written consent, all the patients in both the groups were subjected for thorough clinical examination and investigations which include routine blood counts, ESR, CRP, and AP and lateral X-ray views of the pelvis with both hips. Adequate analgesics, antibiotics, tetanus toxoid, and blood transfusions were given as needed before surgery. Aspirin, anticoagulants and other anti-inflammatory drugs were stopped 7 to 10 days before surgery. Any occult infections like skin lesions, dental caries, and urinary tract infections were identified and treated preoperatively.

The roentgenographic evaluation was done to determine the anatomic relationship of the femur and pelvis to allow for accurate restoration of joint anatomy and biomechanics. The standard pelvic roentgenogram AP view with both hips along with upper-end femur, AP X-ray of the hip in 15 degrees of internal rotation and lateral X-ray of the hip were taken. The

templating was done with the use of plastic overlay templates both for femoral and acetabular components to aid in the selection of the implant size and neck length required to restore equal limb lengths and medial offset (**Figures 1 and 2**).

The medullary canal of the femur was assessed with Dorr's classification in pre-operative radiographs. According to Dorr's classification, group A patients were managed with an uncemented prosthesis and group B and C patients were managed with cemented prosthesis or bone grafting with the excised femoral head [8,9].

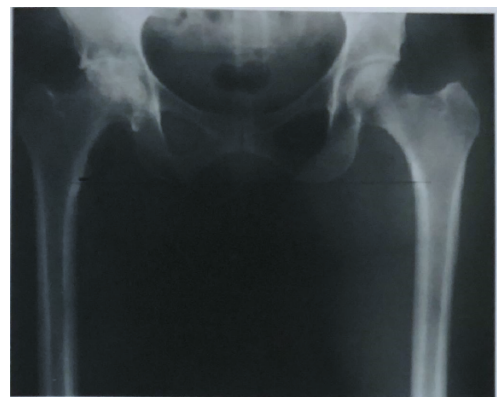


Figure 1: Determination of limb length discrepancy.

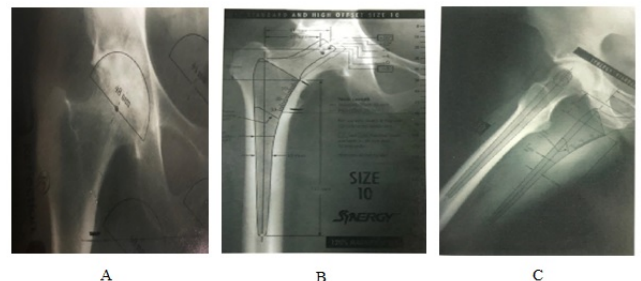


Figure 2: (A): Acetabular templating; (B,C): Femoral templating.

Surgical approach by lateral Hardinge's approach [11,12]

The patient was positioned in the lateral decubitus position with sterile draping techniques. A longitudinal incision of 5 cm proximal to the tip of the greater trochanter and centered over the greater trochanter and extend down along the line of the femur for about 8 to 10 cm's was made. The dissection of superficial fascia lata and detachment of gluteus medius and the exposure of anterior joint capsule and anterior dislocation of the femoral head were performed. The femoral neck osteotomy proceeded with acetabular preparation and removal of osteophytes and loose bodies. The placement of the acetabular cup at 45°-50° of inclination and fastening with an appropriate number of screws were done. The femoral stem was prepared and placement of appropriate stem at 5° to 10° of femoral

anteversion after application of cement if needed after performing trial stem placement. The performance of modular head reduction into the acetabular component proceeded. The stability of the hip joint was observed. Then the wound was closed in layers with the application of sterile drain, as shown in **Figure 3a-3g**.

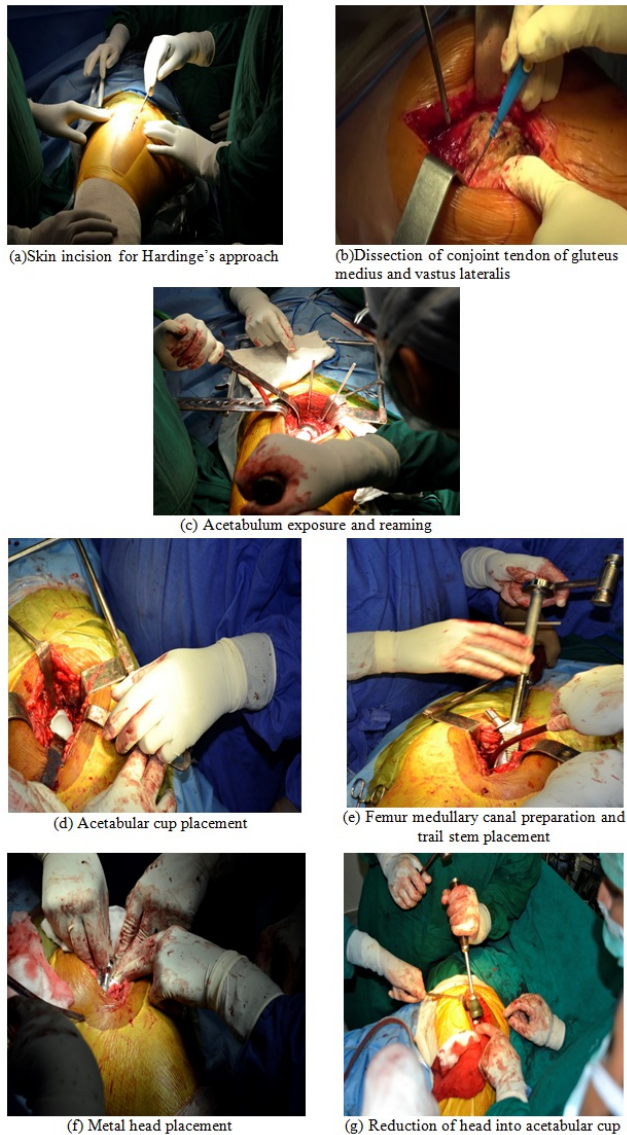


Figure 3: Performing the modular head reduction into the acetabular component by Hardinge's approach.

Surgical approach by posterior Southern Moore's approach [11,12]

The patient was positioned in lateral position over unaffected hip with sterile draping techniques. An incision centering the greater trochanter and 10-15 cm long incision extending from the posterior border of greater trochanter curving posteriorly along the fibres of gluteus maximus 5 cm below the posterior superior iliac spine and from greater trochanter along the shaft for approximately 10 cm was made. The fascia over gluteus medius was incised and uncovering of vastus lateralis was

performed. The gluteus maximus is splitted along the direction of muscle fibres. The sciatic nerve is identified and protected. The short external rotators are identified and cut as close to its insertion over the greater trochanter. Incise the joint capsule in longitudinal fashion or T shaped incision and the dislocate the head by internally rotating the femur and posterior dislocation of the femoral head. The femoral neck osteotomy proceeded with acetabular preparation and removal of osteophytes and loose bodies. The placement of acetabular cup at 45°-50° of inclination and fastening with an appropriate number of screws were done. The femoral stem was prepared and placement of appropriate stem at 5° to 10° of femoral anteversion after application of cement if needed after performing trial stem placement. The performance of modular head reduction into the acetabular component proceeded. The stability of the hip joint was observed. Then the wound was closed in layers with the application of sterile drain, as shown in **Figure 4a-4g**.

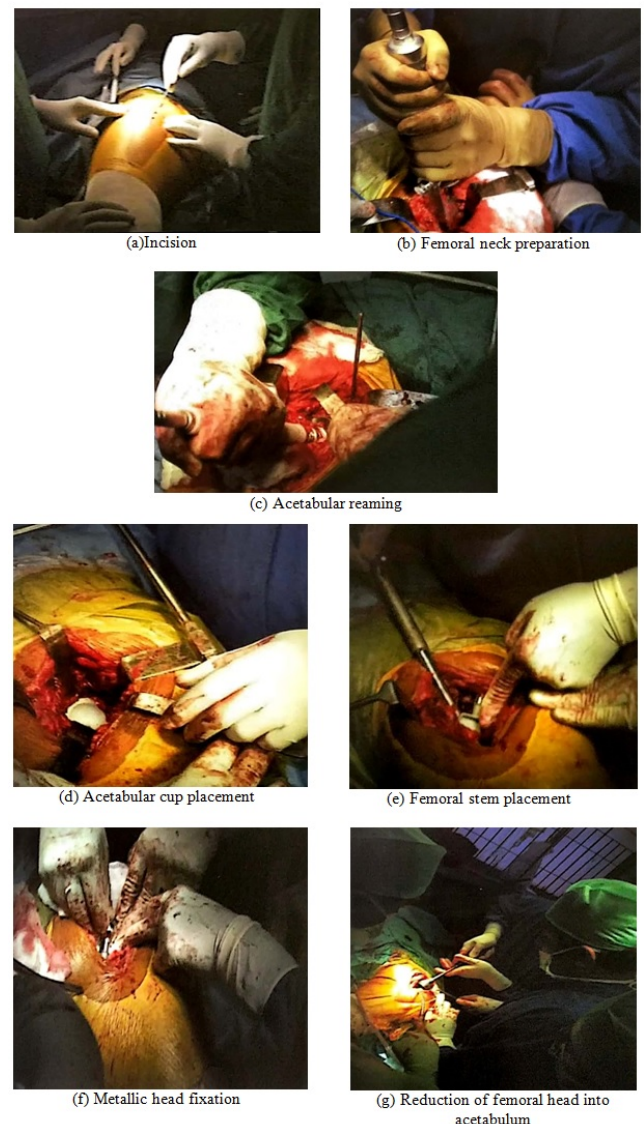


Figure 4: Performing modular head reduction into the acetabular component by Southern Moore's approach.

Post-operative management

The operated limb was kept in abduction with a pillow in between the two lower limbs. The vital parameters were monitored carefully for 24 hours. The check X-ray was performed. The intravenous antibiotics were continued for 5 days. The drain was removed and the tip sent for culture and sensitivity after 48 hours.

The staged physiotherapy was followed for all patients who were involved in our study. The upper limb and chest physiotherapy and static quadriceps exercises were started on the 1st day. The patient was made to sit up on the 3rd day, non-weight bearing standing on the 5th day, walk with help of a foldable walker on the 10th day. The patient was discharged with the advice not to adduct and internally rotate the limb, not to squat and to walk with a walker (protected weight bearing) for 6 weeks.

Follow-up protocol

On discharge, the patients were followed up at the end of 1st, 3rd and 6th and every 1 year thereafter. At the follow-up, a detailed clinical examination was done and the patient was assessed subjectively for symptoms like pain, swelling, and restriction of joint motion. The modified Harris hip scoring system was used for functional evaluation. The check X-rays were taken to study for any signs of complications of the procedure (Figures 5 and 6).

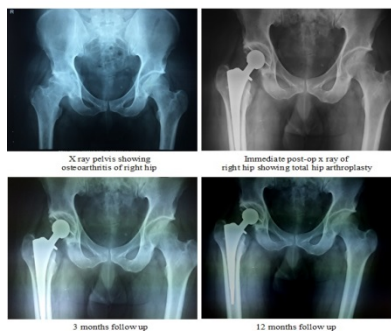


Figure 5: Follow up of total hip arthroplasty by lateral Hardinge's approach.

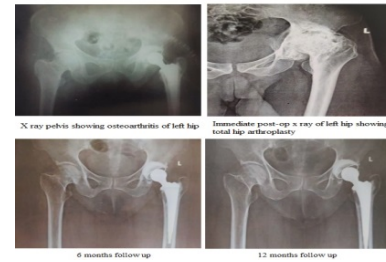

Figure 6: Follow up of total hip arthroplasty by posterior Moore's approach.

Results

A total of 89 patients, who underwent total hip arthroplasty as per the study protocol, were taken into consideration for statistical analysis. The group 'L' patients (n=47) received total hip arthroplasty by Hardinge's approach and group 'P' patients (n=42) received total hip arthroplasty by Moore's approach. The descriptive analytical statistics were evaluated statistically with IBM SPSS Statistics for Windows, Version 20.0, IBM Corp, Chicago, IL.

Among 89 patients in this study, 57 patients (64.04%) were males and 32 patients (35.95%) were females. All the patients belong to age between 38 to 74 years of age. The average age of the study population was 49.63 ± 5.03 years. The sex difference among both the groups were statistically insignificant ($p=1.719$) (Table 1).

Out of 89 patients, 33 patients (37.07%) were due to avascular necrosis of femoral head, 24 patients (26.96%) due to non-union neck of femur, 13 patients (14.60%) due to healed cases of Perthes disease and 9 patients (10.11%) due to primary osteoarthritis of hip, 6 patients (6.74%) due to malunited acetabular fracture and 4 patients (4.49%) due to acetabular dysplasia (Figure 7).

Table 1: Patient's demography according to the study groups.

Age group	Group 'L'-Hardinge's approach (n=47)		Group 'P'-Moore's approach (n=42)	
	No of Males	No of Females	No of Males	No of Females
31-40	3	1	4	3
41-50	9	4	6	4
51-60	13	6	7	4
61-70	5	3	5	4

71-80	2	1	3	2
Total	32 (68.08%)	15 (31.91%)	25 (59.52%)	17 (40.47%)

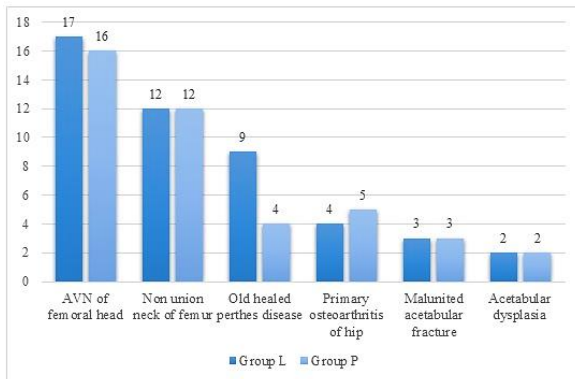


Figure 7: Distribution of cases among 2 groups.

The selection of patients were randomized by selecting every alternate case of degenerative hip disease by lateral Hardinge's (Group 'L', n=47) or posterior Moore's (Group 'P', n=42) approach. We recruited 89 cases for this study and all cases were operated by the same surgeon. All patients were given with a pre-operative dose of third generation IV cephalosporin.

Mullers modular prosthesis was used for all cases. The acetabular cups used were of 28 mm inner diameter and the outer diameter varied from 44 mm to 60 mm. The most commonly used acetabular cup with outer diameter were 46 mm in 62 patients (69.66%), 44 mm in patients (15.73%) and 48 mm in patients (14.60%). The femoral stems range from small to extra-large sizes. The most commonly used femoral stems were small sized in 59 patients (66.29%), medium-sized in 19 patients (21.34%) and large in 11 patients (12.35%). The necks were of small (-4), medium (0), large (+4) and extra-large (+8) sizes. The most common used necks were of medium sized in 44 patients (49.43%), small sized in 23 patients (25.84%) and large-sized in 22 patients (24.71%). The size of the metallic head range from small, medium and large sizes. The most commonly used metallic head were of medium sized (0) in 43 patients (48.31%), small sized (-4) in 29 patients (32.58%) and large-sized (+4) in 17 patients (19.10%).

A total of 43 patients (48.31%) have got cemented total hip arthroplasty and 46 patients (51.68%) underwent uncemented

total hip arthroplasty. A total of 24 patients (55.81%) in group 'L' and 19 patients (44.18%) in group 'P' underwent cemented total hip arthroplasty.

All patients were treated with IV antibiotics for 5 days followed by one week of oral antibiotics. All patients were advised to start dynamic and static quadriceps exercises and ankle pump exercises to prevent stiffness and contractures. The sutures were removed at the end of the 10th post-op day. No intraoperative complications were noted during the surgical procedures. All the patients were followed up serially as per our protocol with serial clinical and radiographical examinations (**Figure 8**).

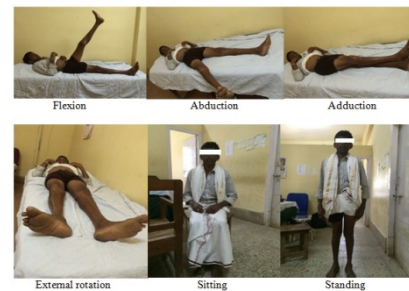

Figure 8: Clinical outcome of total hip arthroplasty by Moore's approach.

The functional assessments were made with modified Harris Hip scores. In group 'L' (n=47), the range of movements were excellent in 32 patients (68.08%), good in 13 patients (27.65%) and poor in 2 patients (4.25%). The poor range of movements (n=2) were due to infection 1 patient and aseptic loosening 1 patient. In group 'P' (n=42), the range of movements were excellent in 26 patients (61.90%), good in 13 patients (30.95%) and poor in 3 patients (7.14%). The poor range of movements (n=3) were due to infection 1 patient and limb length discrepancy 2 patients. At the end of 6th and 12th month, there is a significant statistical difference among both the groups ($p < 0.001$) in terms of functional assessment of modified Harris' Hip scores (**Figure 9 and Table 2**).

Table 2: Functional assessment by Modified Harris' Hip scores.

Duration	Group 'L'(n=47)	Group 'P'(n=42)	p-value
Pre-operative	23.47 ± 5.53	24.91 ± 4.14	2.012
Immediate post op	62.71 ± 3.19	59.24 ± 1.73	0.91
1 st month	69.83 ± 1.49	61.91 ± 2.66	0.493
3 rd month	79.52 ± 2.67	76.87 ± 3.75	0.147

6 th month	86.27 ± 3.19	82.65 ± 1.83	0.03
12 th month	93.13 ± 0.31	89.16 ± 2.37	<0.001



Figure 9: Clinical outcome of total hip arthroplasty by Hardinge's approach.

The most common complication encountered in our study were dislocation 3 patients (3.37%) and limb length discrepancy 3 patients (3.37%) followed by infection 2 patients (2.24%) and loosening 1 patient (1.12%) (**Table 3**).

Table 3: Complications.

Complications	Group 'L' (n=47)	Group 'P' (n=42)	Total (n=89)
Infection	1	1	2 (2.24%)
Vascular injuries	0	0	0
Nerve injuries	0	0	0
Hemorrhage	0	0	0
Bladder injury	0	0	0
Limb length discrepancy (LLD)	1	2	3 (3.37%)
Thromboembolism	0	0	0
Dislocation	0	3	3 (3.37%)
Loosening	0	1	1 (1.12%)
Stem failure	0	0	0
Heterotrophic calcification	0	0	0

Discussion

Total Hip Arthroplasty (THA) has been lauded and proven to be a reliable surgery of choice in relieving pain and dysfunction associated with severe and painful hip arthrosis [13]. The surgeon must have a thorough understanding of the anatomy in order to optimize exposure and implore precise technique to minimize complications and optimize patient outcomes. The most commonly used approaches worldwide for THA include the posterior approach, direct lateral approach, and the direct anterior approach. The primary goal for painful hips is to provide a painless, stable and a mobile hip to the patient. The selection

The infection patients in both group 'L' (n=1) and P (n=1) were treated with culture sensitive IV antibiotics for 2 weeks followed by oral antibiotics for 4 weeks with serial radiographic analysis. The dislocation cases in the post-operative period in group 'P' (n=3) were analyzed and reduced the dislocated hip by closed reduction method under fluoroscopic guidance and abduction splint were given for 10 days. With serial radiographic analysis, the loosening of the implant in group 'P' (n=1) was identified and exchange cemented implant of higher size was used. The Limb Length Discrepancy (LLD) in group 'L' (n=1) and 'P' (n=3) were managed with heel rise if LLD was below 2.5 cm and sole rise if LLD was above 2.5 cm.

The correlation analysis with Spearman's Rank correlation coefficient (ρ) was 0.83 which show a highly positive correlation between Hardinge's approach (Group 'L', n=47) and complications and (ρ) 0.59 which show a moderately positive correlation between Moore's approach (Group 'P', n=42) and complications. There is a significant statistical difference between surgical approach and complications between two groups with $p < 0.05$.

of patients is an important job while planning total hip arthroplasty [14,15].

Goyal et al. [16] suggested cemented implants are preferred over uncemented implants as cemented implants are cheaper and provide pain-free and early full weight bearing than uncemented implants. Mäkelä et al. [17] compared the survival of cemented and uncemented hip replacement prosthesis in patients older than 55 years and concluded that cemented implants have better survival than uncemented implants. Hailer et al. analyzed 10-year survival of cemented and uncemented THR with cemented being better as uncemented implants had

more revisions due to aseptic loosening of the cup [18]. Zimmerma et al. [19] concluded no statistically significant differences in clinical or functional outcomes between uncemented and cemented prostheses up to 12 months post-surgery.

Nachiketan KD et al. [20] stated that the modified direct lateral approach provides easy accessibility to hip joint and excellent exposure of both acetabular and proximal femur. They stated that there was no incidence of prosthesis dislocation in the post-operative period. Jian Li et al. [21] utilized combined anterior and posterior approach to total hip arthroplasty using a lateral incision in patients with severe, spontaneous ankylosis provides very good exposure, protects the abduction unit and results in good to excellent postoperative recovery.

Oscar Skoogh et al. investigated how the relationship between surgical approach and risk of reoperation due to dislocation has evolved over time. They concluded that the increased risk of early reoperations due to dislocations using posterior Moore's approach compared with the direct lateral Hardinge's approach [22]. Gharanzade et al. [23] conducted a study on 134 patients for primary hip arthroplasty. The lateral approach was used in 79 hips and posterolateral approach was used in 55 hips. There was no significant difference between the two approaches regarding demographic characteristics, Harris Hip score, blood loss, transfusion, hemoglobin level, dislocation and cup inclination angle. They observed a statistically significant difference in the incidences of infections, DVT, proximal femur fracture and discrepancy of limb length between the two approaches. They concluded that both approaches offer an excellent return to function and pain reduction after total hip arthroplasty.

The direct lateral and posterior approaches are fundamentally muscle-splitting approaches to the hip. The most important determinants of a successful total hip arthroplasty are mitigation of pain, improved quality of life and restoration of function [24]. Barber et al. [25] prospectively followed for 2 years 28 patients undergoing direct posterior and 21 undergoing direct lateral total hip arthroplasty. Both the groups had similar improvements on the Harris Hip Score at the 2-year follow-up and had no observable differences in complications.

Witzleb WC et al. [26] assigned 60 patients to undergo total hip arthroplasty through either a posterior or lateral approach. The primary endpoint was the HHS, WOMAC, and SF-36 at the 12-week follow-up. Both posterior and lateral approaches showed similar improvements across the HHS, WOMAC and SF-36 questionnaires at 12 weeks postoperatively. A common comparator between the posterior Moore's and lateral Hardinge's approach is the incidence of abductor insufficiency.

Witzleb WC et al. [26], Masonis JL et al. [27], Jolles BM et al. [28] and Iorio R et al. [29] have suggested the direct lateral approach has an increased incidence of abductor insufficiency following total hip arthroplasty. The reported incidence varies from 0% to 16% for the posterior approach and from 4% to 20% for the direct lateral approach.

Potter HG et al. [30], Potter HG et al. [31], Muller M et al. [32] and Pfirrmann CW et al. [33] used the presence of

Trendelenburg gait or lateral trochanteric pain, which may lead to poor inter-rater reliability, to make the diagnosis. Magnetic resonance imaging has become a popular method for assessing soft tissue pathology following total hip arthroplasty. Pfirrmann CW et al. [33] and Twair A et al. [34] have shown that metal suppression pulsed MRI sequences can identify abductor damage in patients with symptomatic abductor tears following total hip arthroplasty.

In our study, Muller's modular prosthesis was used for all cases. Out of 89 patients, a total of 43 patients (48.31%) have got cemented total hip arthroplasty and 46 patients (51.68%) underwent uncemented total hip arthroplasty. The functional assessments with modified Harris Hip scores showed excellent in 32 patients (68.08%), good in 13 patients (27.65%) and poor in 2 patients (4.25%) in group 'L' (n=47) and excellent in 26 patients (61.90%), good in 13 patients (30.95%) and poor in 3 patients (7.14%) in group 'P' (n=42). The complications are higher in group 'P' while comparing to group 'L' in our study. We observed a significant statistical difference between surgical approach and complications between two groups with $p < 0.05$. The limitations of this study were smaller sample size, limited follow-up duration and non-usage of MRI for follow up.

Conclusion

Total hip arthroplasty is an affordable and safe surgical procedure of choice for patients with diseased and destroyed hips to provide a painless, stable and mobile hip post-operatively. In our study, we achieved excellent results by lateral Hardinge's approach with the proper selection of patients, proper planning, adequate implants with the least complications. The lateral Hardinge's approach needs a long learning curve with utmost technical precision. As lateral Hardinge's approach provides wide exposure to the acetabulum and lesser dislocation rates, it is considered superior than posterior Moore's approach.

References

1. Learmonth ID, Young C, Rorabeck C (2007) The operation of the century: total hip replacement. *Lancet* 370: 1508-1519.
2. Charnley J (2005) The long-term results of low-friction arthroplasty of the hip performed as a primary intervention. *Clin Orthop Relat Res* 430: 3-11.
3. Maggs J, Wilson M (2017) The relative merits of cemented and uncemented prostheses in total hip arthroplasty. *Indian J Orthop* 51: 377-385.
4. Abdulkarim A, Ellanti P, Motterlini N, Fahey T, O'Byrne JM (2013) Cemented versus uncemented fixation in total hip replacement: A systematic review and meta-analysis of randomized controlled trials. *Orthop Rev (Pavia)* 5: e8.
5. Inngul C, Blomfeldt R, Ponzer S, Enocson A (2015) Cemented versus uncemented arthroplasty in patients with a displaced fracture of the femoral neck: A randomised controlled trial. *Bone Joint J* 97: 1475-1480.
6. Pennington M, Grieve R, Sekhon JS, Gregg P, Black N, et al. (2013) Cemented, cementless, and hybrid prostheses for total hip replacement: Cost effectiveness analysis. *BMJ* 346: f1026.

7. Thompson R, Kane RL, Gromala T, McLaughlin B, Flood S, et al. (2002) Complications and short-term outcomes associated with total hip arthroplasty in teaching and community hospitals. *J Arthroplasty* 17: 32-40.
8. Palan J, Beard DJ, Murray DW (2009) Which approach for total hip arthroplasty: Anterolateral or posterior? *Clin Orthop Relat Res* 467: 473-477.
9. Mizra SB, Dunlop DG, Panesar SS (2010) Basic science considerations in primary total hip replacement arthroplasty. *Open Orthop J* 4: 169-180.
10. Sathappan SS, Strauss EJ, Ginat D (2007) Surgical challenges in complex primary total hip arthroplasty. *Am J Orthop* 36: 534-541.
11. Angerame MR, Dennis DA (2018) Surgical approaches for total hip arthroplasty. *Ann Joint* 3: 43.
12. Moretti VM, Post ZD (2017) Surgical approaches for total hip arthroplasty. *Indian J Orthop* 51: 368-376.
13. Blemfeldt R, Tornkvist H, Eriksson K (2007) A randomized controlled trial comparing bipolar hemiarthroplasty with total hip replacement for displaced intracapsular fractures of femoral neck in elderly patients. *J Bone Joint Surg Br* 89: 160-165.
14. Morshed S, Bozic KJ, Ries MD, Malchau H, Colford JM (2007) Comparison of cemented and uncemented fixation in total hip replacement: A meta-analysis. *Acta Orthop* 78: 315-326.
15. Espehaug B, Furnes O, Engesaeter LB (2009) 18 years of results with cemented primary hip prostheses in the Norwegian Arthroplasty Register. *Acta Orthop* 80: 402-412.
16. Goyal D, Bansal M, Lamoria R (2018) Comparative study of functional outcome of cemented and uncemented total hip replacement. *J Orthop Traumatol Rehabil* 10: 23-28.
17. Mäkelä KT, Matilainen M, Pulkkinen P (2014) Countrywise results of total hip replacement. *Acta Orthop* 85: 107-116.
18. Hailer NP, Garellick G, Kärrholm J (2010) Uncemented and cemented primary total hip arthroplasty in the Swedish Hip Arthroplasty Register. *Acta Orthop* 81: 34-41.
19. Zimmerma S, Hawkes WG, Hudson JI, Magaziner J, Hebel JR, et al. (2002) Outcomes of surgical management of total HIP replacement in patients aged 65 years and older: Cemented versus cementless femoral components and lateral or anterolateral versus posterior anatomical approach. *J Orthop Res* 20: 182-191.
20. Nachiketan K Dore, Gopi M, Devadoss S, Devadoss A (2017) Functional outcome in patients who have underwent Total Hip Replacement through modified lateral approach for various indications. *Int J Ortho Sci* 3: 161-164.
21. Li J, Wang Z, Li M, Wu Y, Xu W, et al. (2013) Total hip arthroplasty using a combined anterior and posterior approach via a lateral incision in patients with ankylosed hips. *Can J Surg* 56: 332-340.
22. Skoogh O, Tsikandylakis G, Mohaddes M, Nemes S, Odin D, et al. (2019) Contemporary posterior surgical approach in total hip replacement: still more reoperations due to dislocation compared with direct lateral approach? An observational study of the Swedish Hip Arthroplasty Register including 156,979 hips. *Acta Orthopaedica*.
23. Gharanizade K, Heris HK, Abolghasemian M, Joudi S, Panahy PHS, et al. (2016) A comparative evaluation of primary total hip arthroplasty via lateral and posterolateral approaches. *Shafa Ortho J* 3: e3901.
24. Petis S, Howard JL, Lanting BL, Vasarhelyi EM (2015) Surgical approach in primary total hip arthroplasty: anatomy, technique and clinical outcomes. *Can J Surg* 58: 128-139.
25. Barber TC, Roger D, Goodman S (1996) Early outcome of total hip arthroplasty using the direct lateral vs the posterior surgical approach. *Orthopedics* 19: 873-875.
26. Witzleb WC, Stephan L, Krummenauer F (2009) Short-term outcome after posterior versus lateral surgical approach for total hip arthroplasty: A randomized clinical trial. *Eur J Med Res* 14: 256-263.
27. Masonis JL, Bourne R (2002) Surgical approach, abductor function, and total hip arthroplasty dislocation. *Clin Orthop Relat Res* 405: 46-53.
28. Jolles BM, Bogoch E (2006) Posterior versus lateral surgical approach for total hip arthroplasty in adults with osteoarthritis. *Cochrane Database Syst Rev*: CD003828.
29. Iorio R, Healy W, Warren P (2006) Lateral trochanteric pain following primary total hip arthroplasty. *J Arthroplasty* 21: 233-236.
30. Potter HG, Nestor B, Sofka C (2004) Magnetic resonance imaging after total hip arthroplasty: evaluation of periprosthetic soft tissue. *J Bone Joint Surg Am* 86: 1947-1954.
31. Potter HG, Foo L, Nestor B (2005) What is the role of magnetic resonance imaging in the evaluation of total hip arthroplasty? *HSS J* 1: 89-93.
32. Müller M, Thotz S, Springer I (2011) Randomized controlled trial of abductor muscle damage in relation to the surgical approach for primary total hip replacement: minimally invasive anterolateral versus modified direct lateral approach. *Arch Orthop Trauma Surg* 131: 179-189.
33. Pfirrmann CW, Notzli H, Dora C (2005) Abductor tendons and muscles assessed at MR imaging after total hip arthroplasty in asymptomatic and symptomatic patients. *Radiology* 235: 969-976.
34. Twair A, Ryan M, O'Connell M (2003) MRI of failed total hip replacement caused by abductor muscle avulsion. *AJR Am J Roentgenol* 181: 1547-1550.