

DOI: 10.4172/2471-8416.100063

Isolated Fracture of the Antero-lateral Facet of the Coronoid Process with Elbow Instability: A Case Report

Toni Mansour*, Philippe Leclerc and Laurent Casabianca

Department of Orthopaedics, 27 Rue Faubourg Saint Jacques, Paris, France

*Corresponding author: Toni Mansour, Department of Orthopaedics, 27 Rue Faubourg Saint Jacques, Paris, France, Tel: +33635528197; E-mail: drtonimansour@gmail.com

Received date: January 12, 2019; Accepted date: February 20, 2019; Published date: March 01, 2019

Copyright: ©2019 Mansour T, et al. This is an open-access article distributed under the terms of the Creative Commons Attribution License, which permits unrestricted use, distribution, and reproduction in any medium, provided the original author and source are credited.

Citation: Mansour T, Leclerc P, Casabianca L (2019) Isolated Fracture of the Antero-lateral Facet of the Coronoid Process with Elbow Instability: A Case Report. J Clin Exp Orthop Vol.5 No.1:63.

Abstract

Treatment of elbow injuries can be challenging because of the difficulty to achieve reduction and stability, due to the complexity of both anatomy and pathology. Recent studies have demonstrated that the coronoid process plays a key role in elbow stability. Coronoid process is anterior support that prevents ulna from posterior displacement. For the trauma surgeon, this is well analyzed by Regan and Morrey's classification, when the fracture is in the coronal plane. Recently O'Driscoll introduced a more comprehensive classification that includes the anteromedial facet lesion, involved in axial loaded and varus trauma of the elbow, as when falling onto outstretched arm with pronation. This concept explains the concomitant injury of the coronoid process and the lateral collateral ligament, a serious problem for the trauma surgeon, leading to potentially and permanent elbow instability.

In this paper, a non-previously described injury: Fracture of the anterolateral facet of the coronoid process with elbow subluxation has been described.

Keywords: Elbow instability; Coronoid fracture; Lateral collateral ligament; Annular ligament; Postero-lateral rotatory instability; Varus posteromedial instability

Case Report

A 30-year-old, right-hand dominant woman, presented to the emergency department after a fall on the stairs of the subway onto her left outstretched arm. She did not report any sensation of dislocation of the left elbow.

Initial examination revealed hematoma and maximum tenderness over the anterior aspect of the left elbow, as well as mild tenderness over its lateral side. Elbow was blocked in about 70 degrees of flexion due to pain. There was no associated neurovascular deficit, nor pain in the homolateral wrist.

Initial X-rays of the elbow revealed postero-medial subluxation on the AP view, with an anterior bony fragment, and no sign of instability in the lateral view (**Figure 1**).

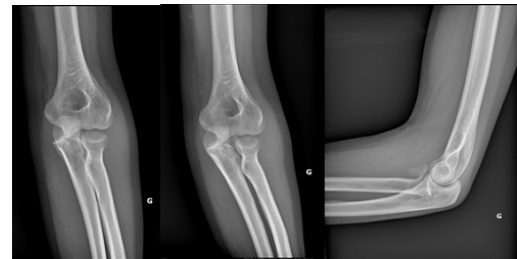

Figure 1: Anteroposterior and lateral X-rays of the left elbow demonstrate a bony fragment lying in the left ante-cubital fossa and a postero-medial subluxation of the left elbow.

A computed tomography scan showed that the fragment measured 25 × 15 mm and originated from the anterolateral facet of the coronoid process (**Figure 2**), thus leaving approximately 60% of the coronoid process intact (**Figure 3**).

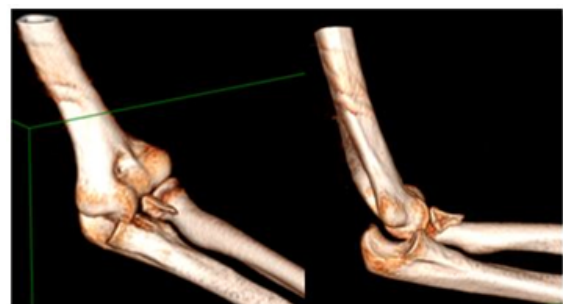

Figure 2: A three-dimensional reconstruction from the computed tomography scan of the left elbow demonstrates the fragment has arisen from the antero-lateral aspect of the ulna coronoid process.

The patient went to the OR the day after the trauma to test the elbow under general anesthesia and for ORIF of the coronoid fracture.

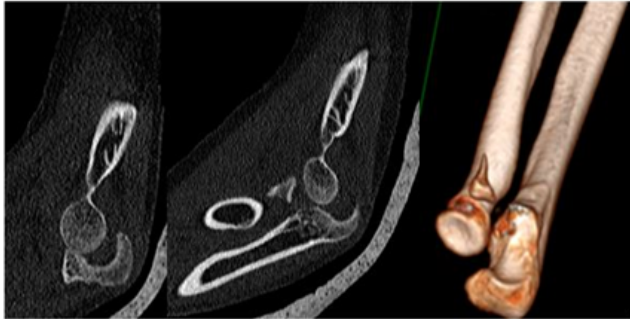


Figure 3: Two dimensional and three-dimensional computed tomography images of the patient's left elbow demonstrate the loss of the anterolateral aspect of the coronoid process with associated posterior subluxation of the humeroulnar joint.

Surgical technique

The patient was supine on a regular and radiolucent table with a tourniquet on arm. The intervention was performed under fluoroscopic control. The testing revealed a permanent subluxated elbow in all positions: Flexion/extension and varus/valgus.

The indication of open reduction and internal fixation was then confirmed.

We thought that a medial approach of the coronoid process was preferable due to the lateral obstacle of the radial head. An antero-medial approach of 6-8 cm was made at 2 cm proximal to the medial epicondyle of humerus and 5 cm distal from the elbow joint. The skin and subcutaneous tissues were dissected. The medial antebrachial cutaneous nerve and the basilica vein were found and protected by blunt dissection of subcutaneous tissues. The ulnar nerve was dissected and protected along the surgical view up to the medial epicondyle level. The bicipital aponeurosis was longitudinally dissected. The intermuscular septum between the pronator teres and the flexor carpi radialis were separated longitudinally along the muscle fibers and unbound at the proximal side. The ridge of medial epicondyle was found and the distal aspect of the anterior humerus was subperiosteally exposed. The pronator teres was retracted to the radial side while the flexors were retracted to the ulnar side. Then, the brachialis was retracted to the radial side. The anterior part of the medial collateral ligament was intact and was protected. The intact antero-medial joint capsule was dissected and opened. The ulnar recurrent artery was located and protected at the lower segment of the surgical field.

The coronoid process was exposed with difficulty due to the small size of the fragment, and an anatomical reduction of the fracture was performed with an elbow in flexion and neutral position of the forearm. Two Kirschner wires were used for

temporary fixation, and definitive fixation was performed using two cannulated 2.5 mm compression screws (Choc LEPINE®).

The elbow joint was observed for stability under fluoroscopic control and was stable along an arc of motion of 0-130 degrees.

Postoperative care

Following the operation, an articulated brace was used to immobilize the elbow joint in an arc of motion of 20-120 degrees, and in the neutral position of the forearm. Routine analgesics and anti-inflammatory drugs were administered. Two weeks after the operation, the patient was able to do limited activities of her elbow. The maximum extension was limited at 20° till the sixth week, with 120 degrees of active flexion. The activities were not limited and the patient returned to normal work 8 weeks after the operation, and returned to swimming 12 weeks after operation (**Figure 4**).



Figure 4: Good functional outcome with no limitation in the arc of motion of the left elbow at 12 weeks follow-up.

The concentric reduction of humero-ulnar joint was guaranteed by double-examination with monthly X-rays within 3 months (**Figure 5**), as well as a CT scan of the elbow at 3 months that demonstrated a complete fracture healing.

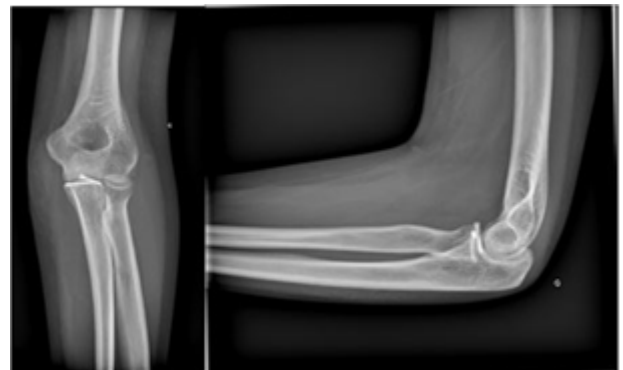

Figure 5: Antero-posterior and lateral X-rays at 3 months post-operatively demonstrate concentric reduction of the elbow joint.

Discussion and Conclusion

It is now well established that fracture of the coronoid is a pattern of potential instability of the elbow. Whether this instability is medial/lateral, posterior or both, it could be analyzed from the plan of the fracture and the width of the fragment observed on the CT scan. Dislocation occurs when more than one of the elbow stabilizer is affected.

Treatment of ulnar coronoid process fracture is the same as that of an intra-articular fracture. Best result can be achieved through anatomical reduction, stable fixation, and early mobilization.

This case presents the surgical management of an isolated fracture of the antero-lateral facet of the coronoid process. As far as we know, this fracture has never been depicted in any of the classifications used to describe fractures of the coronoid process.

Three types of coronoid fracture were described by Regan and Morrey [1]. Type I fractures involve the tip of the coronoid, type II fractures involve more than the tip and less than 50% of the coronoid, and type III fractures involve greater than 50%. There are A and B designations for each type, in which the B indicates associated dislocation [1].

O'Driscoll et al. [2] described a new classification system involving 3 fracture types. Type 1 is a tip fracture, type 2 is an antero-medial facet fracture, and type 3 is a fracture through the base of the process.

Most fractures of the coronoid process occur in association with elbow dislocation or other bony injuries [3]. It is generally accepted that the key factor in determining patient management is the stability of the elbow joint.

Regan and Morrey type III fractures and antero-medial facet fracture described by O'Driscoll are particularly associated with an unstable elbow joint [4,5].

From an anatomical point of view, three structures insert onto the coronoid process: The anterior bundle of the ulnar collateral ligament, the anterior elbow capsule and the tendon of the brachialis muscle. Each of these structures contributes to the stability of the elbow joint.

In our case, the injury of the elbow was unstable and associated with postero-medial subluxation, despite the integrity of the antero-medial facet of the coronoid process, the ulnar collateral ligament, and the brachialis muscle insertion.

Butler et al. [6] reported on an isolated fracture of the antero-lateral facet of the coronoid process of proximal ulna, but, owing to the absence of clinical instability or locked motion on examining the elbow, presence of the antero-medial part of the coronoid process, and absence of damage to the collateral ligaments of the elbow, they decided to treat the patient nonoperatively. The patient was satisfied with the range of motion and function in the elbow, with no further complications reported. According to Butler et al [6], the injury in their case was stable owing to two factors: The integrity of the antero-

medial facet of the coronoid process and the presence of 60% of the joint articulation.

However, in our case, the elbow joint was subluxated with fair incongruence of the articular surfaces on both plain X-rays and computed tomography scan despite the intact antero-medial facet and the integrity of more than 60% of the coronoid process.

Reduction maneuvers conducted in the emergency room were unsuccessful, so we decided to undergo open reduction and internal fixation, and we were satisfied by the postoperative stability of the elbow joint along an arc of motion of 0-130 degrees.

The difference with Butler's report relies probably on a different pattern of lesion highlighted on CT scan examination. Three D reconstructions revealed that the fracture involved almost 50% of the radial notch of the proximal ulna (**Figure 6**).

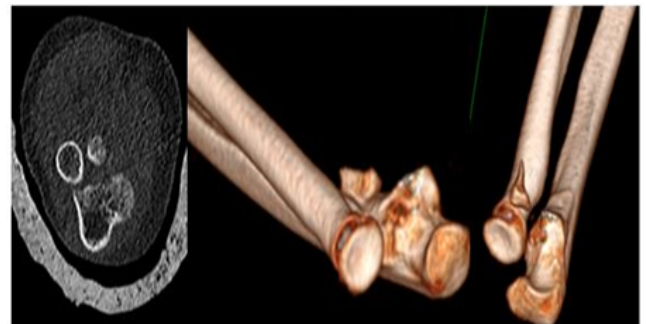


Figure 6: In our case, the fracture of the antero-lateral facet of the coronoid process involves almost 50% of the radial notch articulating with the radial head.

Barnes et al. [7] conducted cadaver elbow dissections to clarify the anatomy of the annular ligament. They described three layers of the lateral elbow ligaments: the superficial lateral ulnar collateral and lateral radial collateral ligament; a second layer consisting of the annular ligament proper and the Superior Oblique Band (SOB) and Inferior Oblique Band (IOB) of the annular ligament; and the deepest capsular layer.

Anteriorly, they have observed two layers: The annular ligament and a newly described Anterior Oblique Band (AOB) compose the superficial layer, and the joint capsule forms the deeper layer. The AOB was observed as a separate structure that runs distal to the anterior portion of the annular ligament and attaches distally on the lateral aspect of the coronoid process distal to annular ligament insertion (**Figure 7**).

This was a cadaveric and anatomic study and the authors didn't analyze the role of the different components of the lateral elbow ligaments in elbow stability.

Hackl et al. [8] studied the functional anatomy of the lateral collateral ligament complex of the elbow. They demonstrate that the lateral ulnar collateral ligament coalesces with the annular ligament at the supinator crest and that the lateral collateral ligament complex in its entirety rather than solely the lateral

ulnar collateral ligament was found to be of importance in preserving elbow stability.

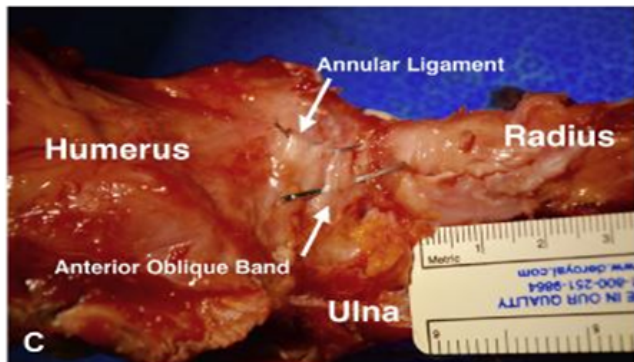


Figure 7: An anterior view of the elbow showing the annular ligament and the Anterior Oblique Band (AOB) inserting at the antero-lateral aspect of the coronoid process of proximal ulna [7].

According to the anatomical and functional studies mentioned above, and the type of instability of the elbow encountered in our case, we would like to describe a new and rare injury pattern: It is the fracture of the antero-lateral facet of the coronoid process that involves the radial notch of the proximal ulna.

This isolated injury is equivalent to an avulsion of the anterior insertion of the annular ligament and its Anterior Oblique Band (AOB) and causes postero-medial subluxation. Divergent dislocation of the elbow could be an extreme consequence [9].

The further anatomical and biomechanical study would clarify this concept and estimate the value of adding this injury to O'Driscoll classification.

References

1. Regan W, Morrey B (1989) Fractures of the coronoid process of the ulna. *J Bone Joint Surg Am* 71: 1348-1354.
2. O'Driscoll SW, Jupiter JB, Cohen MS, Ring D, McKee MD (2003) Difficult elbow fractures: Pearls and pitfalls. *Instr Course Lect* 52: 113-134.
3. Morrey BF (2000). *The elbow and its disorders*. 3rd ed Philadelphia, PA: WB Saunders Company.
4. Doornberg JN, Ring DC (2006) Fracture of the antero-medial facet of the coronoid process. *J Bone Joint Surg Am* 88: 2216-2224.
5. Pollock JW, Brownhill J, Ferreira L, McDonald CP, Johnson J, et al. (2009) The effect of antero-medial facet fractures of the coronoid and lateral collateral ligament injury on elbow stability and kinematics. *J Bone Joint Surg Am* 91: 1448-1458.
6. Butler DP, Alsousou J, Keys R (2011) Isolated anterolateral fracture of the coronoid process of the ulna: A case report. *J Shoulder Elbow Surg* 20: e1-e4.
7. Barnes JW, Chouhan VL, Egekeze NC, Rinaldi CE, Cil A (2018) The annular ligament-revisited. *J Shoulder Elbow Surg* 27: e16-e19.
8. Hackl M, Bercher M, Wegmann K, Müller LP, Dargel J (2016) Functional anatomy of the lateral collateral ligament of the elbow. *Arch Orthop Trauma Surg* 136: 1031-1037.
9. Wu Y, Jiang H, Miao W (2016) A case report of children's divergent dislocation of the elbow and review of literature. *Medicine (Baltimore)* 95: e4772.